

"Virtually any cognitive process can be studied by this technique."

Top: A typical horizontal PET slice. Red areas are most active. Allman is facing the top of the page. Middle: X-ray of Allman's head (facing left) in the MRI format, showing the planes of the 7 horizontal PET slices. Bottom: An unsubtracted PET scan, converted to sagittal format and superimposed on the MRI image.

Head Games

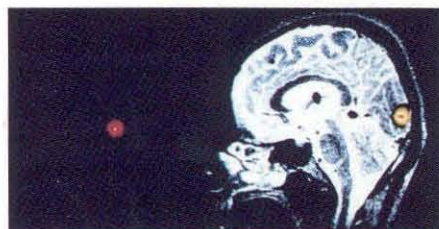
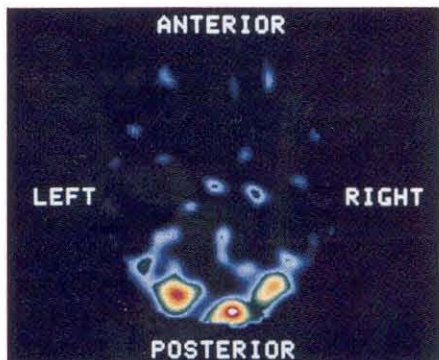
Every student knows the straightest path to success is to get inside your adviser's head, but few do it quite as directly as Bassem Mora. Mora, now a senior in biology (pre-med), took a peek inside Professor of Biology John M. Allman's brain as his SURF project last summer.

The brain's complex anatomy is a mirror for the complex functions it performs. Specific areas of the brain perform specific tasks. The visual cortex, which converts nerve impulses from the eyes into what we see in our mind, lies at the rear of the brain, in the occipital lobe. The brain has been mapped in broad outline, based on decades of individual medical histories—a tumor here, and the patient no longer recognized faces, but could identify people when they spoke; a lesion there, and the patient lost the use of the left hand. Electrodes have charted the ebb and flow of the brain's electricity. But, short of taking the top off someone's skull for a direct look, how can one relate a burst of electrical activity to a specific lump of tissue in a living person?

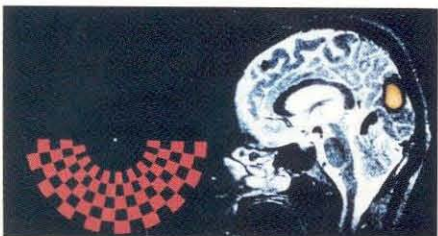
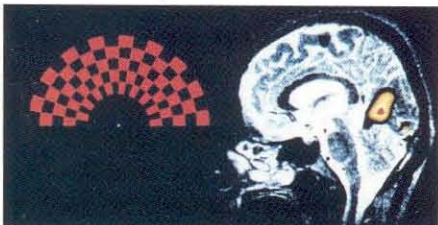
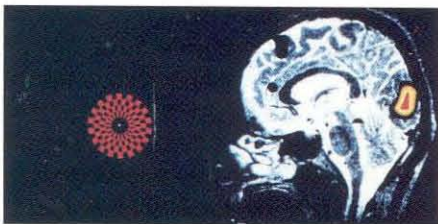
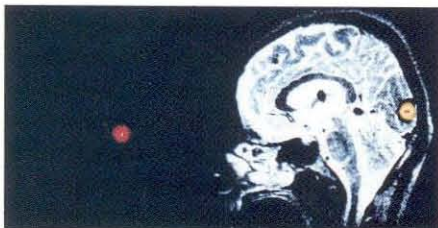
Mora developed a computer program that matches activity to anatomy. The program combines two images made by different techniques. Both techniques, Magnetic Resonance Imaging (MRI) and Positron Emission Tomography (PET), are standard diagnostic tools for noninvasive looks inside the body—in this case into Allman's brain.

MRI produces detailed three-dimensional anatomical images much in the same way that a CAT scan does. MRI, however, does not bombard the body with potentially harmful x-rays, but instead immerses the body in a magnetic field and records its response to radio waves. MRI scans are clearer and more detailed than CAT scans. Bones register very strongly in CAT scans, obscuring softer tissue, but bones do not generate strong MRI images—a critical consideration for brain imaging. The MRI scans were made by Dr. William G. Bradley, Jr., (BS '70, and a pioneer in MRI for medical uses) at the Huntington Medical Research Institute in Pasadena.

PET scans depict cellular activity but show few recognizable anatomical features. Active regions register as bright areas, while less active regions are proportionately dimmer. PET actually measures variations in blood flow. About 20 milliliters (roughly four teaspoons) of water labeled with oxygen-15, a short-lived tracer with a half-life of 123 seconds, is injected into the bloodstream. Greater blood flow to active regions brings more ¹⁵O there, just in time for it to emit a positron and decay to ordinary nitrogen-15. The PET scans were made by Dr. Mark Raichle and his team at the Washington University Medical School in St. Louis, Missouri. "It takes a small army of people to make a PET scan," Allman remarked. "¹⁵O decays so fast that they have to make it on the spot. So they make it in a cyclotron down in the basement, and then shoot it upstairs to the imaging lab through



Subtracted PET scans superimposed on the MRI scan. Allman is facing left, toward the corresponding visual stimulus. Note how the bottom half-checkerboard registers higher in the brain than the top half-checkerboard.



a pneumatic tube.”

Since the brain is active even when the body is at rest, a single PET scan is a blurry, uninformative thing. But by making two of them, and subtracting one from the other in the computer, subtle changes become obvious. A background scan was made while Allman was lying quietly, eyes closed and wearing earplugs. Then Allman opened his eyes and looked at a series of flashing patterns on a video screen. Another scan was made for each pattern. (A special headrest keeps the head stationary, eliminating movement errors between scans. “It was a very comfortable couch, actually,” Allman recalls. “They take great pains to make sure you’re perfectly relaxed. Once you’ve settled into position, the whole series of scans takes two to three hours, and if you start to fidget, you ruin them.”) When the background scan was subtracted from a pattern scan, only a small region of the visual cortex remained. Other researchers had done similar experiments, and had been able to show that various patterns stimulated different bits of the cortex, but without precise anatomical landmarks it was impossible to tell exactly what patch of gray matter had lit up.

Superimposing MRI and PET images is a bit more complicated than just aligning two pieces of film on top of each other and holding them up to a strong light. Each complete image is actually a series of slices through the brain, a fixed distance apart, taken simultaneously. The MRI scan has 10 slices taken sagittally (in vertical planes running front to back) spaced 2.7 millimeters (mm) apart, while the PET scan has 7 horizontal slices spaced at 14.4 mm intervals. Furthermore, each MRI slice consists of a matrix of 256×256 pixels (“picture elements”), while the PET slice contains 100×100 pixels. Each pixel in the MRI image represents a cube of tissue measuring 0.95 mm front to back, 0.95 mm top to bottom, and 2.7 mm left to right. Each PET pixel is 2.7 mm \times 14.4 mm \times 2.7 mm.

Mora’s program had to transform 7 horizontal PET slices into 10 sagittal ones to match the MRI scans, taking into account the size differences between their pixels. A conventional x-ray, taken while Allman was still in the PET headrest, showed the exact orientation of his head during the scans, and provided anatomical details that Mora could match to the MRI scans. The MRI data arrived at Caltech on magnetic tapes in a format that Mora’s computer couldn’t read. No one knew how that format worked, so Mora spent several days figuring it out for himself. According to Allman, “It was a remarkable accomplishment. Most people—professionals included—would have thrown in the towel right there. There were other hurdles, too—although the idea was straightforward, this was not an easy project.”

The resulting superpositions clearly show the specific lumps and strands of cortical tissue that responded to each stimulus. As more of the retina was stimulated, larger areas of cortical tissue responded. Furthermore, the areas were inverted—a stimulus in the lower half of the visual field lit up an area closer to the top of the skull than did the mirror image stimulus in the upper half of the field. (The latter phenomenon had been inferred from patients recovering from gunshot wounds—small-caliber bullets destroy a very narrow column of tissue along their immediate path, which can usually be determined with great accuracy.)

“Virtually any cognitive process could be studied by this technique,” Allman says. “The St. Louis group is using it right now to study speech, and we expect a lot of other people to start using it.” In the meantime, Mora is continuing with the project this summer with a variant of MRI that tracks the adenosine triphosphate (ATP) that fuels the brain’s electrical activity. Besides being a more direct measure of brain function than PET, this strategy uses no radioactive tracers, and the whole thing can be done in one machine—perhaps even at one time. □—DS